



## Variations of the superficial palmar arches: A cadaveric study

Humberto Ferreira Arquez<sup>1\*</sup> and Diana Katherine Arias Hurtado<sup>2</sup>

<sup>1</sup>Professor of Human Morphology, Medicine Program, Morphology Laboratory Coordinator, University of Pamplona, Pamplona, Norte de Santander, Colombia, South America

<sup>2</sup>Medicine Student Twelfth Semester - University of Pamplona

---

### ABSTRACT

Awareness of the anatomical variations of the blood supply of the hand is necessary not only for the anatomist but also for surgeons when considering hand surgery. The objective of this study was investigate the incidence of anatomical variations of the superficial palmar arch and describe an rare anatomical variation. A total of 14 cadavers were used for the study in the laboratory of Morphology of the University of Pamplona. In the right hand, the superficial palmar arch only gave rise to two common palmar digital arteries. In the left hand, the arch provided common palmar digital arteries which ran into the first, third and the fourth spaces and one proper palmar digital for the little finger. The arch does not supply the second intermetacarpal space. Less critical knowledge of vasculature of the hand might lead iatrogenic injury during surgery of the hand.

**Keywords:** Anatomical variations, superficial palmar arch, deep palmar arch, ulnar artery, radial artery, common palmar digital arteries.

---

### INTRODUCTION

The hand is supplied by the terminal branches of the radial and ulnar arteries. The blood supply of the hand is derived from the superficial and the deep palmar arches (respectively SPA and DPA). The superficial palmar arch is an anastomosis fed mainly by the ulnar artery. The later enters the palm with the ulnar nerve, anterior to the flexor retinaculum and lateral to the pisiform. It passes medial to the hook of the hamates, and then curves laterally to form an arch, convex distally and level with a transverse line through the distal border of the fully extended pollicial base. About a third of the superficial palmar arches are formed by the ulnar alone; a further third are completed by the superficial palmar branch of the radial artery and a third by the arteria radialis indicis, a branch of arteria princeps pollicis or the median artery. Four digital arteries arise from the convexity of the arch and pass to the fingers. The most medial artery supplies the medial side of the little finger and the remaining three subdivide into two and supply the contiguous sides of the little, ring, middle, and index fingers, respectively. The superficial palmar arch is covered by palmaris brevis and the palmar aponeurosis and it is superficial to flexor digiti minimi, branches of the median nerve and to the long flexor tendons and lumbricals [1,2].

The anatomy of the hand is of significant interest to various disciplines of science. The arterial supply of the human hand is of major importance given its clinical relevance. A thorough knowledge of the arterial supply of the hand is imperative when carrying out procedures such as radial artery conduits in coronary artery bypass grafting (CABG), radial arterial cannulation and reconstructive surgery of the hand [2]. The Vascular patterns of the palmar arches and their interconnecting branches present a complex and challenging study. Many attempts have been made to classify

these variations. One of the first reports that presented a classification of palmar arches was the classic work of Coleman and Anson [3].

The vascular anatomy of the hand is challenging due to a high prevalence of previously identified variations. These variations were usually found in the palmar arches of which the superficial palmar arch (SPA), through which the hand receives its major blood supply, has been shown to be more variable. The SPA has been described to be broadly divided into two categories: complete and incomplete. The difference resides in the presence or absence of an arch formed either by a single artery or between the constituting vessels. Variations seem to be more prevalent within the complete arch category. The variations that occur in the arch are known to be more frequent on the radial side. This may involve one or more interconnecting branches. In view of its importance, the study of the intricate vascular pattern of SPA has continued to receive much interest following advances in microsurgical procedure for reconstructive hand surgery. Awareness of the frequency of these arterial variations has been observed to be of great assistance in preparation and planning for safe hand surgery. Such procedures are now preceded by arterial cannulation in order to determine the exact vascular pattern and hence minimize any potential tissue damage [4-10]. The objective of this study was investigate the incidence of anatomical variations of the superficial palmar arch and describe an anatomical variation unknown, as it is the first case reported so far in the literature.

### EXPERIMENTAL SECTION

A total of 14 cadavers of both sexes (13 men and 1 women) with different age group were used for the study. Upper limb regions (28 sides) of the cadavers were carefully dissected as per the standard dissection procedure in the Morphology Laboratory at the University of Pamplona. The hands were dissected by first removing the skin covering the flexor surface of the hand with a slight extension proximal to the wrist joint and then distally in the palm to the bases of the digits. The ulnar and radial arteries identified proximal to the wrist were preserved. All collected superficial palm Arches were allocated according to the classification of Lippert and Pabst (1985), which determines two main types: Complete and incomplete arches. A complete arch (Type A) is found when there exists an anastomosis between at least two arteries. Following subtypes can be determined [from reference 11]:

LPA1 ("classic" radioulnar type or Arcus radioulnaris): Anastomosis between the ulnar artery and the superficial branch of the radial artery.

LPA2 (medianoulnar type or Arcus medianoulnaris): Anastomosis between the ulnar and median artery.

LPA3 (radiomedianoulnar type or Arcus radiomedianoulnaris): Anastomosis between the ulnar, median and radial artery.

LPA4 (profundoulnar type or Arcus profundoulnaris): Anastomosis between the ulnar artery and the deep branch of the radial artery as the first dorsal interosseus artery or deep palmar arch.

LPA5 (medianoradial type or Arcus medianoradialis): Anastomosis between the superficial branch of the radial artery and the median artery.

An incomplete arch (Type B) does not provide any anastomosis with following subtypes:

LPB1: the ulnar artery forms an arch without anastomosis to other vessels (ULNAR type). LPB1a is including braches to the ulnar side of the thumb and LPB1b is supplying including the index but not the thumb.

LPB2: ulnar and radial artery reaches the palm and gives branches to fingers.

LPB3: ulnar and median artery reaches the palm and gives branches to fingers.

LPB4: ulnar, median and radial artery reaches the palm and gives branches to fingers.

Descriptive statistic was used by assessing each dissection course separately as well as for the total result. In addition the collected data were categorized according to Jaschtschinski's classification (1897), which categorizes as follows:

Complete arch (JA):

JA1: radioulnar type (corresponds to LPA1).

JA2: medianoulnar type (corresponds to LPA2).

JA3: radiomedianoulnar type (corresponds to LPA3).

JA4: Ulnar type (correspond to LPB1a!): reaching at least the radial side of the thumb.

JA5: radiomedian type.

Incomplete arch (JB): no anastomosis between an artery and additional branches from the ulnar artery only to the fingers III, IV and V.

## RESULTS AND DISCUSSION

All the specimens had a superficial palmar arch. From all the superficial palmar arch which were dissected 92.86% (26 cases) were complete superficial palmar arch (complete SPA) where the formations was by Contribution to the superficial palmar arch from the superficial palmar branches from both the radial (RA) and ulnar arteries (UA). Type A, subtype: LPA1,

In 7,14% (2 cases in the same cadaver) were incomplete superficial palmar arch (incomplete SPA) with formations from ulnar artery alone. Type B, subtype: LPB1a, and an unusual arterial pattern of ramification:

### In the right hand:

Brachial artery terminates into radial and ulnar artery in the cubital fossa and the radial artery runs superficial in the forearm and on reaching the wrist curves dorsally and crosses the anatomical snuff box and the ulnar artery enters the hand superficial to the flexor retinaculum along with the ulnar nerve. The radial artery does not give off the superficial branch. The ulnar artery lies lateral to the nerve throughout its course and its superficial branch forms the SPA which gives off the two common digital arteries from the arch which again divides into two proper digital arteries. The arch only gave rise to two common palmar digital arteries what supply the medial and the lateral sides of the third and fourth intermetacarpal space and the lateral side of little finger, lateral and medial side of the ring finger and the medial side middle finger. It was not formed the proper digital branch to the ulnar side of little finger. Deep palmar arch directly contributing to the circulation of the thumb, index finger and the lateral sides of the middle finger. Figure 1.

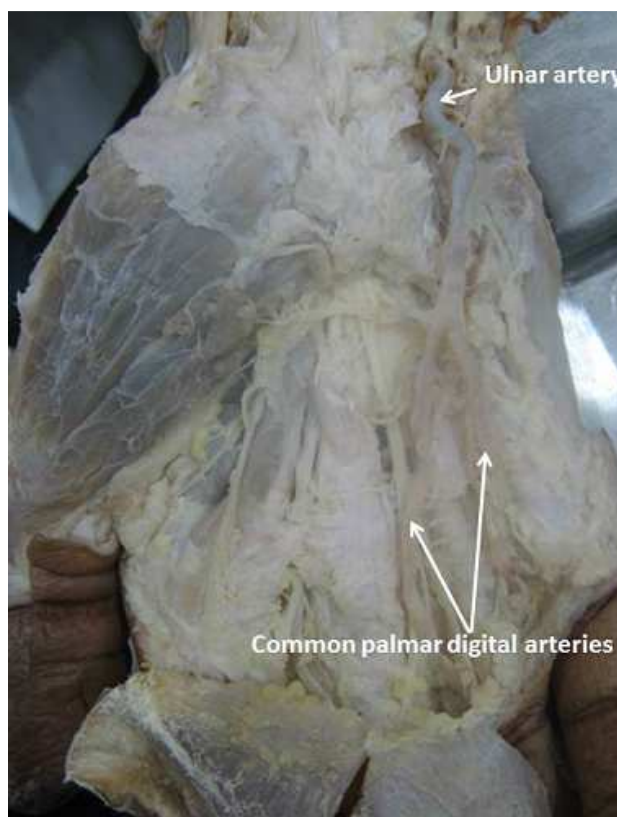


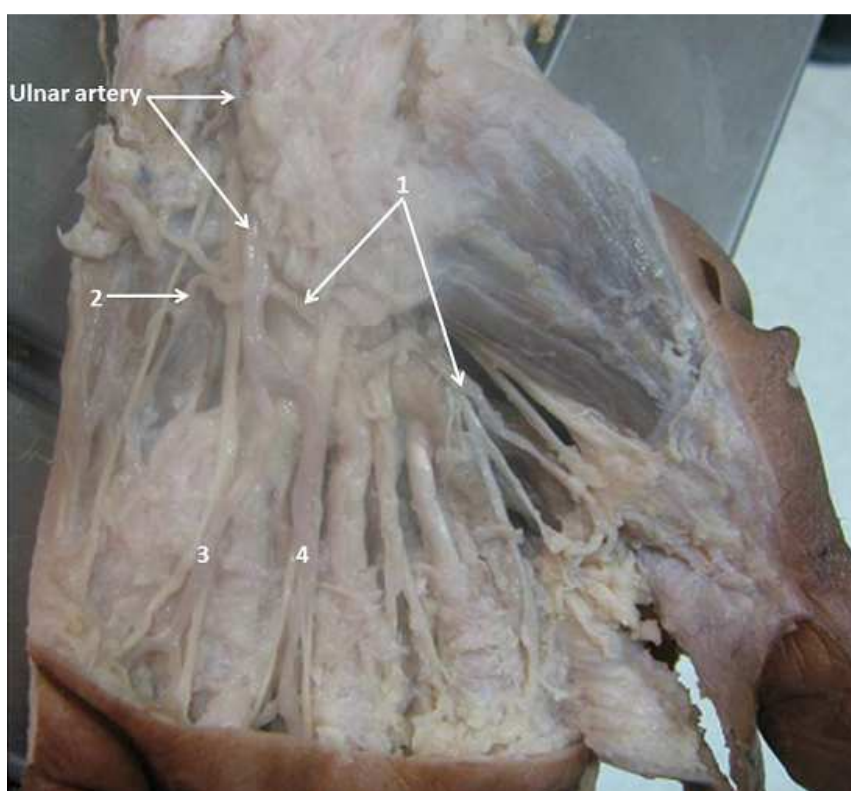
Figure 1. Right hand exhibiting incomplete superficial palmar arch

In the left hand:

Brachial artery terminates into radial and ulnar artery in the cubital fossa and the radial artery runs superficial in the forearm and on reaching the wrist curves dorsally and crosses the anatomical snuff box and the ulnar artery enters the hand superficial to the flexor retinaculum along with the ulnar nerve. The radial artery does not give off the superficial branch. The ulnar artery lies lateral to the nerve throughout its course and its superficial branch forms the superficial palmar arch.

The arch was devoid of the superficial branch of the radial artery. It was solely formed by the ulnar artery on the palmar region and it provided three common palmar digital arteries which ran into the first spaces and provide three proper digital branch to the nourishing thumb and index finger (one princeps pollicis artery, PPA and two radialis indicis artery, RIA); from to the third and the fourth spaces between the corresponding digits and one proper palmar digital artery which ran along the ulnar side of the little finger.

The arch does not supply the second intermetacarpal space and the medial sides of the index finger and lateral sides of the middle finger which are supply for the deep palmar arch. Figure 2.



**Figure 2.** Left hand exhibiting incomplete superficial palmar arch: 1: Common palmar digital artery for the first intermetacarpal space. Note: the trifurcation of the artery in proper digital branch to the nourishing thumb and index finger (one princeps pollicis artery, PPA and two radialis indicis artery, RIA); 2: proper digital branch to the ulnar side of little finger; 3,4: Common palmar digital arteries and common digital branches to the adjacent sides to little, ring, and middle. Note: Absence of the common palmar digital artery to the second intermetacarpal space, this space was supplied by the first common palmar metacarpal artery from the deep palmar arch.

First descriptions of frequencies and variations of the superficial palmar arch (SPA) were collected in the 19th century. Jaschtschinski [11], created a classification concerning the variability of SPAs which was used by other authors Coleman and Anson [3], figure 3; Gellman et al [5]; Ikeda et al [7]. Jaschtschinski [11] determined complete and incomplete arches with different subtypes. In the category of complete arches he lists the radioulnar arch, medianoulnar arch, radiomedianoulnar and ulnar arch. Latter one is the most important to be an arch formed by the ulnar artery only. What is more, Jaschtschinski subdivides the ulnar arch as well developed to send arteries to the thumb's both sides or a "weak" developed one with the first palmar digital common artery to reach only the thumb's ulnar side. However, he clearly determines the ulnar arch to reach the entire thumb or parts of it. Simultaneously it is

one of the key points which can change the results dramatically. Adachi [12] tried to classify his 200 collected hands according to Jaschtschinski's classification but failed to finish it. As a consequence he describes more or less many different types without any classification of complete or incomplete. This should be seen as a very important message that Jaschtschinski's classification should always be regarded critically, cannot be borrowed entirely but has to be adapted. Moreover the paper of Coleman and Anson [3] concerning the arterial patterns of the SPA does include some contradictions. In this paper the authors followed the Jaschtschinski's classification but defined an arch as complete in case of anastomosis between vessels. Certainly this cannot be because Jaschtschinski's ulnar arch does not contain any anastomosis. In addition, Coleman and Anson [3] state to have found a not yet described type providing an anastomosis between the ulnar artery and the deep arch. Well, this corresponds to one subdivision of Jaschtschinski's radioulnar arches. Regarding other, later published papers such as Gellman et al. [5], they include the same concept as Coleman and Anson [3] had happened. However, Lippert and Pabst [13]. Figure 4, published a classification to be in contrast to Jaschtschinski's due to its terminology because they determined a complete arch in case of anastomosis between at least two vessels no matter how large the anastomosis might be. As a consequence, Lippert and Pabst [13] list 4 subtypes of complete arches and 5 subtypes of incomplete arches. Most important difference to Jaschtschinski's classification is that Jaschtschinski's ulnar arch is not found in the category of complete but incomplete arches. Additionally it is defined as a variation to reach at least the radial side of the index. As this variation shows high frequency of development in our investigation between 84.1% and 96.7% of all developed incomplete arches and 21.8% and 45.6% in total result category, it does make a difference in which category the ulnar arch is allocated to. Regarding the ulnar arch more precisely, another important detail must be considered. Jaschtschinski determined this arch to reach at least the thumb on its ulnar side whereas Lippert and Pabst [13] include the radial side of the index. As a consequence, it is crucial that the "ulnar arch" has to be defined precisely which of the fingers has to be reached [14].

The radial artery enters the palm through the upper end of the first metacarpal space between the heads of the first dorsal interosseus muscle. In the palm it lies between this muscle and the adductor pollicis. It anastomoses with the deep palmar (volar) branch from the ulnar artery to continue as the deep palmar arch. At the wrist the radial artery gives off two branches, namely the dorsal carpal artery and the first dorsal metacarpal artery. The arteria princeps pollicis arises from the radial just as it turns medial ward to the deep part of the hand. It descends along to the ulnar side of the metacarpal bone of the thumb to the base of the first phalanx, where it divides into two branches. These appear between the medial and lateral insertions of the adductor pollicis obliquus and form an arch over the palmar surface of the last phalanx from which arise branches to the integument and subcutaneous tissues of the thumb. The radialis indicis artery is another branch of the radial artery. It anastomoses with the proper digital artery to supply the ulnar side of the index finger. At the lower border of the adductor pollicis transversus this vessel anastomoses with the princeps pollicis and gives a communicating branch to the superficial palmar arch. The deep palmar arch is formed by the anastomosis of the terminal part of the radial artery and the deep palmar branch of the ulnar artery. It gives off the palmar metacarpal arteries, the perforating branches and the recurrent branches [2].

The ulnar artery begins at the neck of the radius and descends to the wrist. Just above the wrist it becomes superficial between the tendons of the flexor carpi ulnaris and the flexor digitorum superficialis. It pierces the deep fascia proximal to the flexor retinaculum and gives off its deep palmar branch. (This anastomoses with the radial artery) The ulnar artery continues as the superficial palmar arch. In the wrist the ulnar artery also gives off the volar carpal branch, also known as the palmar carpal branch or the anterior ulnar carpal artery and the dorsal carpal branch also known as the posterior ulnar carpal artery. The superficial plantar arch is thus formed by the ulnar artery and usually completed by a branch from the volaris indicis radialis artery more commonly known as the radialis indicis artery of the radial artery. It is however sometimes completed by the superficial volar branch also known as the superficial palmar artery which arises from the radial artery in the forearm. In some instances the superficial palmar arch has been found to be completed by the princeps pollicis artery of the radial artery [2].

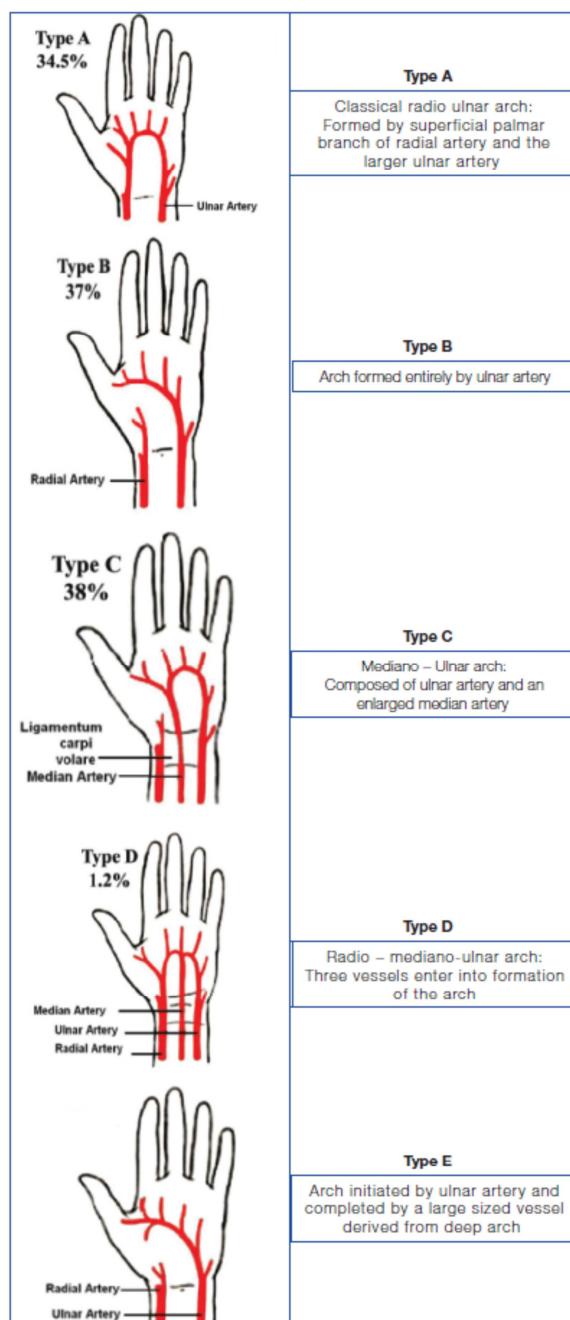


Figure 3. Classifications of Coleman and Anson (from reference 1)

The superficial palmar arch is an arterial arcade which lies adjacent to the palmar aponeurosis. The arch begins on the flexor retinaculum immediately distal to the pisiform bone; it crosses the hook of the hamate deep to the Palmaris brevis. It turns laterally and pierces the medial septum of the palm. It continues deep to the palmar aponeurosis to anastomose with branches of the radial artery as mentioned above. The superficial palmar arch has many branches the main ones being the four digital arteries [2]. The superficial palmar arch can be complete or incomplete. Incomplete superficial palmar arches are clinically important because individuals who have them are at increased risk of digital ischemia. In a study by Coleman et al., the complete arch was found in 78.5% of the cases and incomplete arch in the remaining 21.5% [3]. A study conducted by Ikeda et al. using 220 cadaveric specimens identified the complete superficial palmar arch in 96.4% of the cases and an incomplete palmar arch in 3.6% [7].



Gellman et al. showed a complete superficial palmar arch in 84.4% of cases [5], while Al Turk and Metcalf also reported complete superficial palmar arch in 84% of the cases [15]. According to Williams P et al, about one - third of the SPA is formed by the ulnar artery alone; a further third is completed by the superficial palmar branch of the radial artery and a third either by the arteria radialis indicis or by the princeps pollicis or by the median artery (The median artery is a branch of the anterior interosseous artery which is a branch from the ulnar artery. The median artery arises in the forearm and accompanies the median nerve) [15]. Furthermore this study states that the classical type of the superficial palmar arch in which the superficial branch of the ulnar artery anastomoses with the superficial branch of the radial artery is found in only 34.5% of cases. In 2009 a study was done by Bataineh et al using 30 formalin fixed cadaveric hands. A rare case was reported in there study in which an incomplete superficial palmar arch was formed by the median artery which gave rise to the princeps pollicis and radialis indicis arteries [2,16].

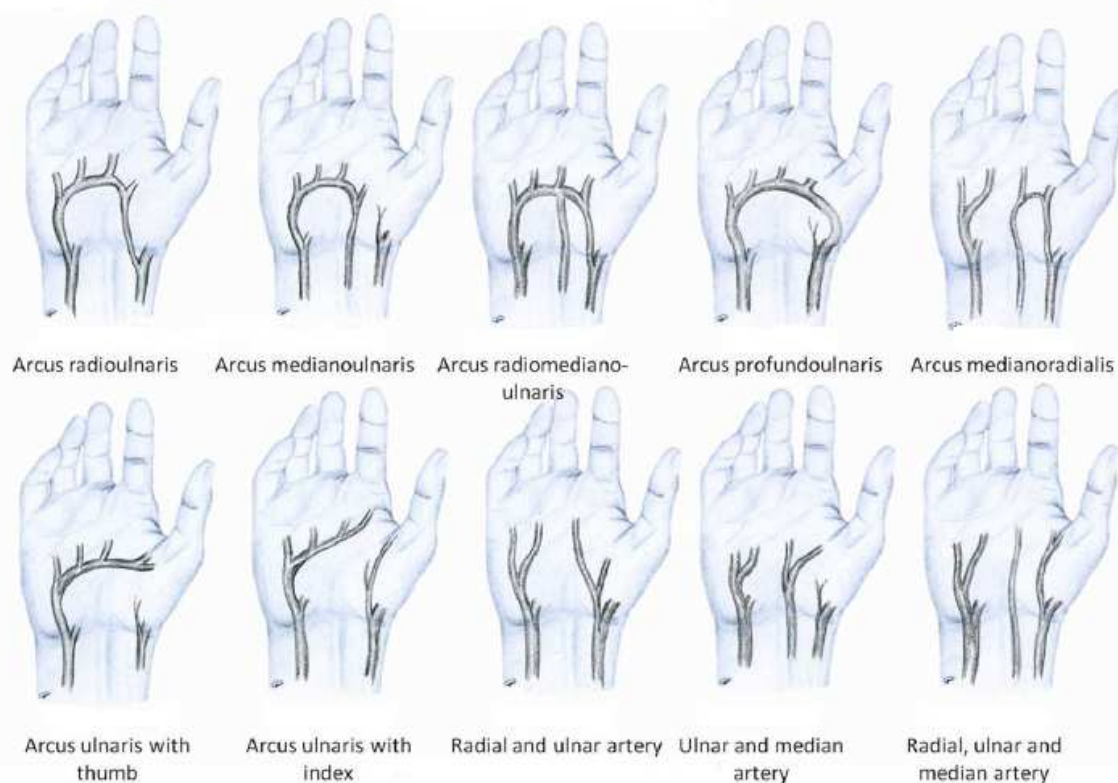

Figure 4. Classifications of Lippert and Pabst (from reference 14)

Little et al. [17] noted that the circulatory dynamics in the hand follow a very variable pattern, the ulnar artery being the dominant source of supply in the most hands. They concluded that collateral circulation in the hand would generally maintain viability of fingers when either radial or ulnar artery was occluded at the wrist. However, they found that in 9% of the hands, there was drastic disturbance of circulation on occlusion of ulnar artery. They suggested that the variation in collateral adequacy in the hand may explain ischaemic phenomena seen in some patients with the hammer hand syndrome [21].

Hypothenar hammer syndrome occurs in persons who use hand as a hammer. Any finger could become ischaemic following occlusion of ulnar artery or superficial volar arch depending upon the pattern of branching present in the superficial arch and the distribution of digital arteries [18,21].

Loukas et al [19] reported a case of complete superficial palmar arch which had no contribution from radial artery and terminated by giving rise to a common trunk for the princeps pollicis and radialis indicis arteries. They stated that as the arterial supply of the thumb in this case is solely provided by superficial palmar arch, a potential hazard could exist in the event of traumatic injury to the ulnar artery [21].

Mookambicaet al [20] reported a case where the superficial palmar arch was formed exclusively by superficial branch of ulnar artery, without contribution by any other vessel. Ulnar artery continued as the first common digital artery to the interdigital cleft between index finger and thumb and this digital artery was dividing into arteria princeps pollicis (APP) or arteria radialis indicis (ARI). They called this type of arch as incomplete SPA based on Gellman classification of palmar arches. They stated that the nomenclature of arteries originating from SPA and supplying thumbs and index finger have to be discussed because of their surgical importance. In hand surgeries like vascular graft applications, arterial repairs, free/pedicle flaps clinicians should be aware of these variations, because in most of the traumatic events and the surgical procedures of hand, SPA plays an important role. In case of ulnar skin flaps, damage to the ulnar artery may present a risk. Interference with an efficient blood supply may result in inefficient utility of the movements of fingers and hand. Superficial palmar arch is the main vascular structure of palm. Hence knowledge about the variation in its pattern is important for surgeons dealing with reconstructive hand surgeries and restorations of functional anatomy of hand. Techniques like Doppler ultrasound, modified Allen test, pulse oximetry and arterial angiography or a combination of the standard Allen test and ultrasonography can be used to identify the vascular pattern of the palm [20,21].

With the recent advances in the field of endoscopic surgical removal of the radial artery reported by Connelly et al. [22] and their promising results, it is apparent that the use of the radial artery as a coronary artery bypass graft(CABG) is being met with some degree of approval. Connelly et al. [22]reported the use of the radial artery in 60% of coronary bypass cases. They reported a reduction in infection rate, discomfort, scarring and possible neurological deficiency, even in patients with such complicating factors as diabetes or peripheral vascular disease. The removal of the radial artery endoscopically can be performed by a properly trained physician's assistant in as little as 15 min. The reported poor longterm performance of saphenous vein grafts [23] allows one to remain cautiously optimistic regarding the use of this novel technique in the future.

Various diagnostic procedures have been implemented to assess the viable collateral circulation in the hand. Gull published a case of pseudoaneurysm in an eighty years old male which was diagnosed by using contrast enhanced computerized tomography angiography and Doppler, which were used to delineate the details of the aneurysm and the collateral circulation [24]. The modified Allen's test is considered as a primary screening method due to its feasibility and Doppler ultrasonography can be used as an alternative, in case unsatisfactory results are obtained by using the former test [25]. A collateral circulation is the remedy for diseases of the palm, which can be established by an anastomosis between the radial and the ulnar arteries [26]. The radial and the ulnar arteries are the main sources to the palm and the further supply can be added by the median and the interosseous arterial systems. The collateral circulation can be assessed by using the modified Allen's test, Doppler ultrasound, pulse oximetry and arterial angiography [27].

Developmental evidence suggests that on reaching the hand the ulnar artery links with the superficial palmar plexus from which superficial palmar arch originates, while the median artery loses its distal connection and is reduced to a small vessel. The superficial arch can be reinforced by a large median artery which arises frequently from the anterior interosseus artery [28]. The proportion of hands in which the median artery made a contribution to the superficial palmar arch was reported as 6% by Anitha et al.,[29]. Rodriguez et al described the palmer type of median artery, representing its embryonic pattern as large, long and reaching the palm [30]. They suggest that radial artery acquires its final state by stage 21 of the embryo and any variations in the formation of SPA may be due to persistence or enlargement of initial network of vessels which normally regress or remain as capillaries. Embryological basis for high origin of superficial ulnar artery and its contribution in the formation of SPA has been reported by Natsis et al. [31] and Reddy et al. [32]. Ikeda et al., [7] also suggest that an inhibition of the development of the vessels at different stages of the embryonic period may be the causes of arterial congenital anomalies.

In the present study, complete SPA formation was observed in 92.86% (26 hand). In the present case the only major communication between radial artery and deep branch of ulnar artery was completion of the deep palmar arch. This cadaver showed bilateral presentations of incomplete superficial palmar arch with an exclusive vascular pattern, which did not show absolute similarity with finding of the above mentioned studies. Regarding the anatomical variation described, we believe that the knowledge of this unusual shape is extremely important, especially because the influence it can exert on the conduct of clinical or surgical procedures.



## CONCLUSION

The proper knowledge of frequency of anatomical variations of vasculature of the hand is very important for safe and successful procedures in order to avoid or minimize the risk of complications during vascular surgeries or reconstructive surgery in the hand. A review of vascular pattern prior to invasive or intervention surgery is strongly recommended, which would allow to detect anomalies likely to necessitate modification of surgical procedures.

## Acknowledgements

The author (s) thanked to the University of Pamplona for research support and/or financial support and Erasmo Meoz University Hospital for the donation of cadavers identified, unclaimed by any family, or persons responsible for their care, process subject to compliance with the legal regulations in force in the Republic of Colombia.

## REFERENCES

- [1] Joshi et al, *JCDR.*, **2014**, 8(4), 6-9.
- [2] LSS Salgado et al, *JAMR.*, **2014**, 1(2), 61-67
- [3] SS Coleman; BJ Anson, *Surgery, Gynaecology, Obstetrics.*, **1961**, 113:409-424.
- [4] H Bianchi, *Hand Clin.*, **2001**, 17, 139-146.
- [5] H Gellman; MJ Botte; J Shankwiler; R Gelberman, *Clin. Orthop. Relat. Res.*, **2001**, 383, 46-47.
- [6] PSF Valeria; TB Celso; HS Jefferson; GC Abadio; ARF Omar, *J. Anat.*, **2004**, 204, 307-311.
- [7] A Ikeda; A Ugawa; Y Kazihara; N Hamada, *J. Hand Surg.*, **1998**, 13, 501-509.
- [8] O Bilge; Y Pinar; MA Ozer; F Govsa, *Surg. Rad. Anat.*, **2006**, 28, 343-350.
- [9] N Jelacic; S Gajisin; A Zbrodowski, *Acta Anat.*, **1988**, 132, 187-190.
- [10] G Mbaka et al, *IJAE.*, **2014**, 119(3), 153-162.
- [11] SN Jaschtschinski, *Anat. Hefte.*, **1897**, 7, 161-188.
- [12] B Adachi, Arcus mediana. In: Adachi, B. (Ed.), *Das Arteriensystem der Japaner*, vol. 1. Kenkyusha, Kyoto, **1928**, 364-368.
- [13] H Lippert; R Pabst, In: Bergmann, J.F. (Ed.), *Arterial variations in man*. Urban & Schwarzenberg, München. **1985**, 71-77.
- [14] GC Feigl et al, *Annals of anatomy.*, **2012**, 194, 389-395.
- [15] M Al-Turk; WK Metcalf, *J Anat.*, **1984**, 138, 27-32.
- [16] ZM Bataineh; O Habbal; ST Moqattash, *Ital J Anat Embryol.*, **2009**, 114(1), 11-20.
- [17] JM Little et al, *Brit J Surg.*, **1973**, (60), 652-655.
- [18] Conn et al, *Surgery.*, **1970**, 68 (6), 1122-1128.
- [19] M Loukas et al, *Singapore Med J.*, **2009**, 50 (11), e391-392.
- [20] RV Mookambica et al, *IJAV.*, **2010**, 3, 65-66.
- [21] Suman et al, *J. Anat. Soc. India.*, **2011**, 60(2), 199-201.
- [22] MW Connelly; LD Torrillo; MJ Stauder; NU Patel; JC McCabe; DF Loulmet; VA Subramanian, *Ann Thor Surg.*, **2002**, 74, 502-506.
- [23] WH Johnson 3rd; RS Cromartie 3<sup>rd</sup>; JE Arrants; JD Wuamett; JB Holt, *Ann Thorac Surg.*, **1998**, 65, 1167.
- [24] S Gull; AJ Spence; W Loan, *Case Reports in Medicine.*, **2011**, Article ID 595120, 3 pages, doi: 10.1155/2011/595120.
- [25] P Ruengsakulrach; N Eizenberg; C Fahrer; M Fahrer; BF Buxton, *J Thorac Cardiovasc Surg.*, **2001**, 122, 682-686.
- [26] VR Vollala; S Nagabhooshana; M Rao; BK Potu; N Pamidi; SR Bolla, *Cases Journal.*, **2009**, doi: 10.4076/1757-1626-2-6362.
- [27] ZM Bataineh; Moqattash, *Folia Morphol.*, **2006**, 65, 406-409.
- [28] Tonse et al, *JDMS.*, **2014**, 13(3), 100-103.
- [29] T Anitha; S Kalbande; D Dombe et al, *Int J Biol Med Res.*, **2011**, 2(2), 543-546.
- [30] MN Rodriguez; JR Sanudo; T Vazquez et al, *J O Anat.*, **1999**, 195, 57-63.
- [31] K Natsis; AL Papadopoulou; G Paraskevas; T Totlis; P Tsi, *Folia Morphol.*, **2006**, 65, 400-405.
- [32] S Reddy; VR Vollala, *J Vasc Bras.*, **2007**, 6(3), 285-288.